

OCULAR LYMPHOMA



CyberKnife® Team:

Radiation Oncologist: Sucha O. Asbell, M.D.
Jorge E. Freire, M.D.
John P. Lamond, M.D.
Luther W. Brady, M.D.

Ophthalmologist: Carol Shields, M.D.

Medical Physicist: Jun Yang, Ph.D.

CyberKnife Center: Philadelphia CyberKnife
Havertown, PA

OCULAR LYMPHOMA

DEMOGRAPHICS

Sex: Female
Age: 46 years
Histology: Non-Hodgkin's Lymphoma B cell type

CLINICAL HISTORY

Referred by: Ophthalmologist
Past Medical History: Stage IIIA Non-Hodgkin's Lymphoma

Case History

A 46-year-old female with a history of Stage IIIA Non-Hodgkin's Lymphoma previously treated with chemotherapy presented with rapid onset of right proptosis and diplopia after being clinically free of disease for one year. The patient had been complaining of visual disturbances for several months prior. MRI scan at the time of the patient's presentation with her new acute right ocular symptoms revealed a mass in her right orbit which on biopsy was consistent with recurrence of her Non-Hodgkin's Lymphoma.

CyberKnife® Treatment Rationale

The location and histology of this patient's tumor limited her treatment options and she refused systemic therapy. To maximize the patient's chances of retaining vision in the right eye, surgical resection was also not deemed appropriate. CyberKnife radiosurgery was recommended to provide rapid regression and to maximize the opportunity for local control within the right orbit while minimizing any damage to the optic nerve and other critical structures. In addition, the potential for a good cosmetic outcome of treatment was felt to be highest with the CyberKnife System. Through the use of hundreds of uniquely angled beams and sub-millimeter accuracy, the CyberKnife System could allow delivery of high doses of radiation in a short time necessary for local control while sparing the nearby critical structures.

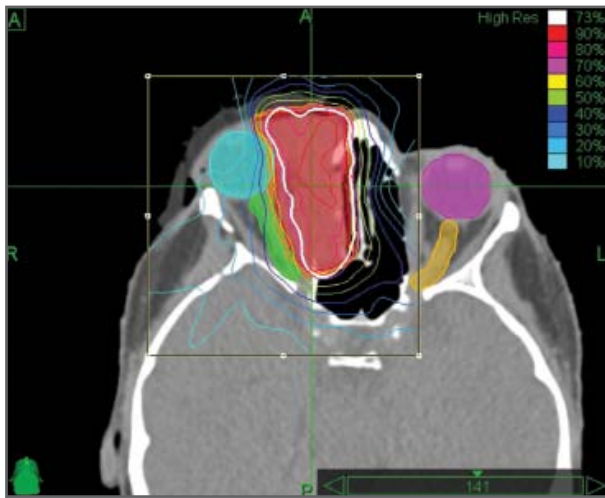
TREATMENT DETAILS

Treatment Volume: 36.1 cc
Imaging Technique(s): CT/MRI
Dose & Fractions: 3.2 Gy x 5 fractions
Conformality Index (PTV): 1.26
Rx Dose & Isodose: 16 Gy to 73%

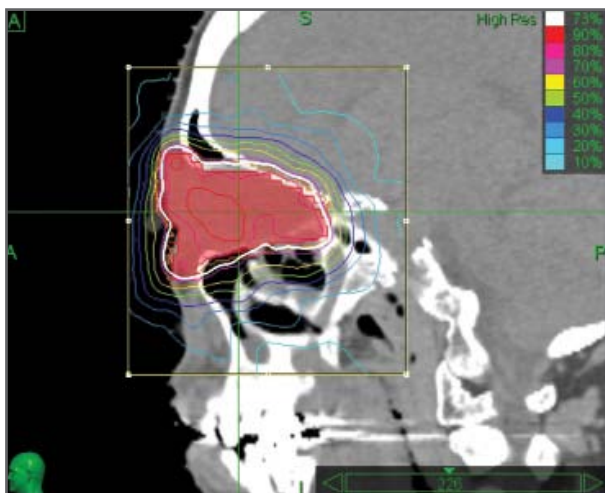
Number of Beams: 188 beams/fraction
Tracking Method: 6D
Collimator(s): 12.5 and 25 mm
Tumor Coverage: 95.6%

Planning Process

The patient underwent CT/MR scanning with an Aquaplast mask. MRI and CT images were then fused to optimally delineate the target volume and the critical structures. Treatment planning goals included keeping the total optic nerve dose to within tolerance and ensuring that no beams passed through the left eye.



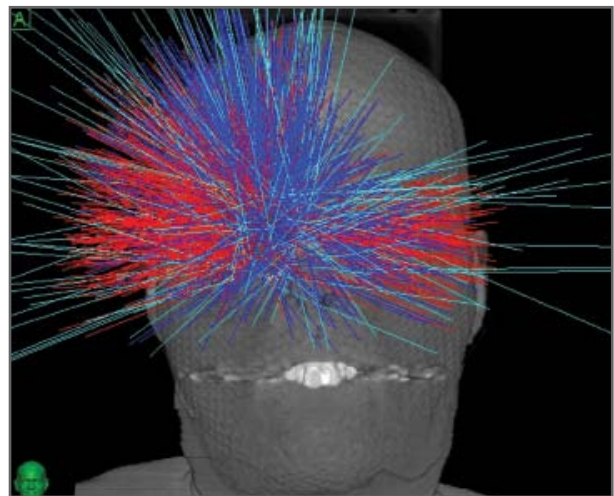
Axial view of the treatment plan showing the highly conformal dose distribution with steep dose fall off. Note sparing of the right eyeball (blue) as well as the right optic nerve (green). The white line indicates the prescription dose to the 73% isodose line.



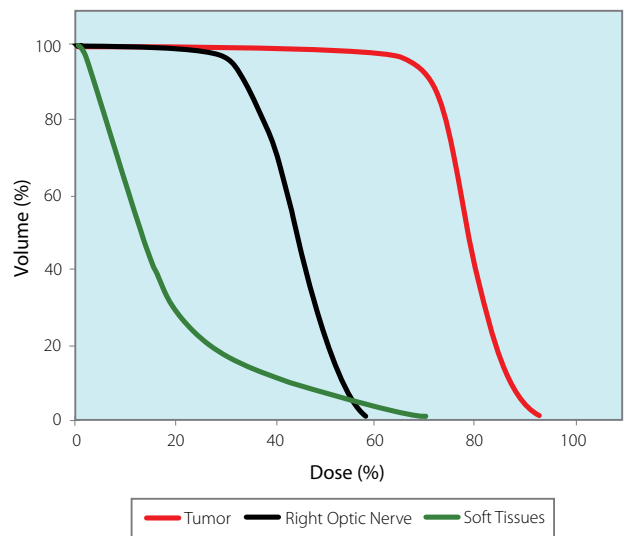
Sagittal view of the treatment plan showing the highly conformal dose distribution with steep dose fall off. The white line indicates the prescription dose to the 73% isodose line.

Treatment Delivery

CyberKnife® treatment was delivered using the 12.5-mm and 25-mm collimators, with 188 active beams. A total dose of 16 Gy in five fractions of 3.2 Gy to the 73% isodose line covering the 36.1 cc target was delivered. The patient was positioned supine with an Aquaplast face mask and B cup headrest. Treatment was performed completely non-invasively using 6D skull tracking.



Coronal view of a 3D representation of the 188 CyberKnife beams delivered per fraction to the tumor within the right orbit.



Dose Volume Histogram (DVH) for the right orbit tumor, right optic nerve and peri-optic soft tissues

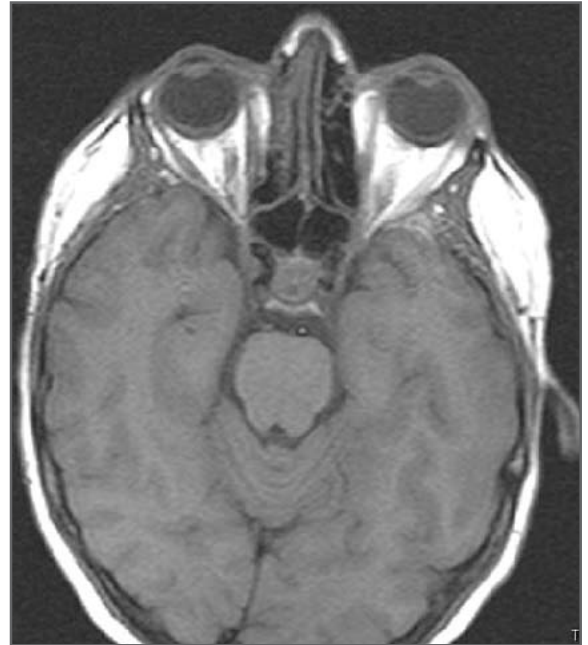
OCULAR LYMPHOMA

Outcome and Follow-Up

- The patient's response was rapid; within days her proptosis and diplopia completely resolved and visual function returned to normal
- She was able to delay starting new chemotherapy for a few weeks which would have made her too ill to attend her daughter's wedding; she was able to attend the wedding appearing normal, feeling well and without visual symptoms
- Complete radiographic response was maintained at the patient's last follow-up visit, 14 months post-treatment; she was also clinically without evidence of local recurrence within the right orbit

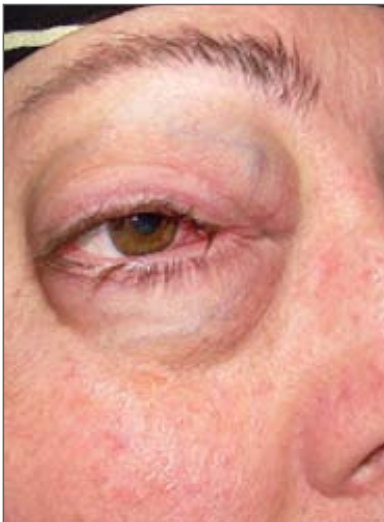
Conclusion and CyberKnife® Advantages

- CyberKnife treatments allowed for rapid palliation of the patient's symptoms while preserving patient's vision
- Complete radiographic response was obtained without any noted acute or chronic toxicity
- The CyberKnife System allowed completion of treatment within one week, allowing patient to resume normal activity quickly

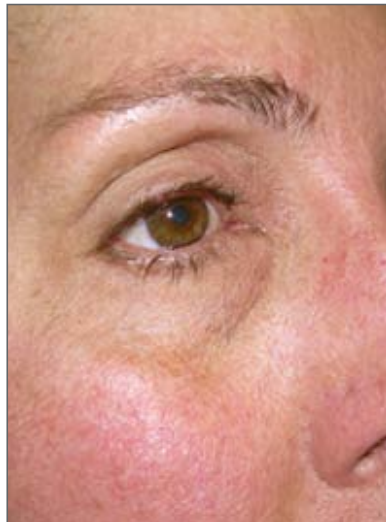

Follow up MRI 14 months post-treatment. Note complete obliteration of the treated mass in the right orbit.

Before



After



Images of the patient taken just before (left panel) and at completion (right panel) of treatment. Note the near complete cosmetic response immediately following the completion of the fifth day of treatment.

PHILADELPHIA CYBERKNIFE

The Philadelphia CyberKnife, the first Cyberknife System in the greater Philadelphia area, was installed in February 2006. It has treated more than 500 patients under the direction of Luther W. Brady, M.D. The center has trained over 40 local Surgeons and Radiation Oncologists who use the facility through the Crozer-Keystone Health System. Contact the Philadelphia CyberKnife at 610-446-6850.

